

Treatment of severe temporomandibular joint clicking with botulinum toxin in the lateral pterygoid muscle in two cases of anterior disc displacement

Merete Bakke, DDS, PhD, Dr Odont,^a Eigild Møller, DDS, Dr Odont,^b Lene M. Werdelin, MD, DMSc,^c Torben Dalager, MD,^d Noriyuki Kitai, DDS, PhD,^e and Sven Kreiborg, DDS, PhD, Dr Odont,^f
Copenhagen

UNIVERSITY OF COPENHAGEN AND COPENHAGEN UNIVERSITY HOSPITAL

A novel treatment procedure is introduced for severe clicking of the temporomandibular joint (TMJ) associated with anterior disc displacement (ADD), using injections with botulinum toxin (BTX-A) in the lateral pterygoid muscle (LP). It has been suggested that ADD may be caused, precipitated, or maintained by LP activity, but the role of the LP in the dynamics of the TMJ clicking is uncertain. The case report includes 2 women, followed with clinical examinations, TMJ imaging, and electromyography (EMG), in whom local anesthetics in the LP could abolish the clicking for several days. BTX-A block of the LP (30 U Botox, given twice under EMG guidance with 6-month interval) temporarily reduced the action of the muscle, but the clicking was permanently eliminated and did not return during the observation period of 1 year, and a small but distinctive positional improvement in the disc-condyle relationship was obtained. However, the precise mechanisms behind the favourable treatment outcome are unclear. (**Oral Surg Oral Med Oral Pathol Oral Radiol Endod 2005;100:693-700**)

Displacement of the articular disc (ADD) is one of the major findings in temporomandibular disorders (TMD) as well as the most common cause for temporomandibular joint (TMJ) sounds.¹ Such reciprocal clicking has been reported in 7% of Scandinavian adults.² However, not all joints with displaced discs produce symptoms, because TMJ structures have large normal variation.³ Larheim et al⁴ found reducing disc displacements (ADD_R), mainly partial, in about 25% of asymptomatic subjects by TMJ magnetic resonance imaging (MRI). ADD_R is generally acknowledged to be associated with or resulting from degenerative processes.^{4,5} The TMJ has a large adaptive capacity, but factors such as age, systemic illness, previous injuries, and excessive or sustained loading may perturb the balance between

catabolic and anabolic responses of the articular tissue, producing disc hesitation and stretching of the attachments, which constitutes a possible risk factor for ADD_R.^{3,6} In most cases of untreated symptom-producing ADD_R, the clicking sound and the maximum jaw opening remain unchanged, while eventually associated tenderness of masticatory muscles decreases.⁷ The symptoms from ADD_R are generally weak to moderate and only require reassurance and observation. With more severe symptoms and signs, including loud joint sounds and pain on jaw movements, conventional treatments have been splint therapy, therapeutic exercises, and surgery.⁸⁻¹⁰ Often, the joint clicking does not change considerably with conservative treatment,¹¹ and surgical treatment for ADD_R in terms of arthroscopy and disc repositioning has little effect.⁹

The lateral pterygoid muscle (LP) is mainly active in horizontal movements of the condyle and generates contralateral and protrusive force.¹² In general, 3 main functions of the LP are reported: (1) to produce lateral movements by unilateral muscle action, (2) to move the disc and condyle in a forward direction by bilateral muscle action, and (3) to stabilize the disc-condyle complex.¹³ The LP has 2 heads, and the function of the 2 heads may differ,¹⁴ even if intermingling of muscle bundles between the different heads has been observed anatomically.¹⁵ It attaches to the capsule and the pterygoid fovea of the mandibular condyle, and may also insert directly into the disc.^{13,16} It has been proposed that uncoordinated function between the muscle bundles of the upper head and the superior part of the lower head of the LP could lead to unstabilized movements of the disc.¹⁵ In addition, a relation between

^aAssociate Professor, Department of Oral Medicine, Clinical Oral Physiology, Oral Pathology and Anatomy, School of Dentistry, University of Copenhagen, Denmark.

^bProfessor Emeritus, Department of Neurology, Bispebjerg Hospital, Copenhagen University Hospital.

^cConsultant, Department of Neurology, Bispebjerg Hospital, Copenhagen University Hospital.

^dDepartment Physician, Department of Clinical Neurophysiology, Bispebjerg Hospital and Rigshospitalet, Copenhagen University Hospital.

^eAssociate Professor. On leave from Graduate School of Dentistry, Osaka University, Osaka, Japan.

^fProfessor, Departments of Pediatric Dentistry and 3D-Laboratory, School of Dentistry, University of Copenhagen, and The Juliane Marie Centre, Copenhagen University Hospital.

Received for publication Jul 15, 2004; returned for revision Nov 11, 2004; accepted for publication Nov 17, 2004.

1079-2104/\$ - see front matter

© 2005 Elsevier Inc. All rights reserved.

doi:10.1016/j.tripleo.2004.11.019

Table I. Characteristics of the unilateral TMJ disc displacement disorder (AAD_R) before treatment with BTX-A of the ipsilateral lateral pterygoid muscle

Patient no.	TMJ with disorder	Duration of TMJ disorder	TMJ clicking	TMJ catching	TMJ pain and capsular tenderness	Associated muscle tenderness	TMJ radiography
1	Right	20 yr	Loud reciprocal clicking during jaw opening and left-sided chewing	No catching episodes	Moderate TMJ pain after repeated clicking Moderate tenderness of right TMJ	Moderate tenderness of right masseter muscle	Normal translation of the condyles and no osseous changes
2	Left	7 yr	Loud reciprocal clicking during jaw opening	Frequent catching episodes elicited during chewing, singing, and sleep	Moderate tenderness of left TMJ	Moderate tenderness of masticatory muscles, especially on the left side	Normal translation of the condyles and slight deviation of the morphology of the left condyle

disc displacements and attachment of the LP directly into the disc has been indicated,¹⁷ and a close relationship has been claimed between ADD_R and the activities of the LP in electromyographic (EMG) studies.^{18,19} However, the role of the LP in the dynamics of the TMJ clicking is uncertain. Our intention was to reduce its part in condylar movement to see the effect on the clicking. Therefore, the treatment first comprised an injection with local anesthetics to block the ipsilateral LP and then, with positive effect on the clicking, to give a prolonged block with botulinum toxin A (BTX-A).

BTX-A is potent biologic toxin acting by temporary chemical denervation of skeletal muscle. BTX-A acts at the presynaptic junction by blocking the Ca²⁺-mediated release of acetylcholine from nerve endings of alpha and gamma motor neurons, producing a transient dose-dependent weakening of the muscle activity without systemic effects.²⁰ The effect peaks within the first 2 months and generally lasts about 4 months.^{21,22} Doses of 2.5 to 60 U Botox (botulinum type A) have been used for treatment of the LP.²³ Previous reports on BTX-A treatment for TMD have dealt with recurrent TMJ dislocations,²⁴⁻²⁶ reduced jaw opening capacity,^{27,28} masticatory hyperactivity,²⁹ and TMJ and masticatory muscle pain.^{30,31} To our knowledge, no other study has applied BTX-A for the treatment of ADD_R. The present case report includes 2 Caucasian Danish women with long-lasting severe TMJ clicking, treated at the School of Dentistry and Bispebjerg Hospital, University of Copenhagen.

PATIENTS AND METHODS

Patients

Two female patients, Patient 1 (54 years old) and Patient 2 (23 years old) with longstanding, unilateral

disc displacement disorder of the TMJ (Table I) were included after written informed consent. No predisposing or precipitating factors for the disorder were found in Patient 1, and Patient 2 associated her joint condition with a trauma from a bicycle accident 7 years earlier. Except for the TMJ disorder the patients were healthy and without prescribed medication. No general joint conditions or musculoskeletal disorders were present. The TMJ disorder fulfilled the classification of the American Academy of Orofacial Pain for disc displacement with reduction (AAOP 11.7.2: reproducible joint noise that occurs usually at variable positions during opening and closing mandibular movements, soft-tissue imaging revealing displaced disc that improves its position during jaw opening, and hard tissue imaging showing an absence of extensive degenerative bone changes).³²

The initial opening click was very loud and directly audible in both patients. It was painless, but repeated clicking produced soreness of the TMJ in Patient 1 (Table I). The clicking could be prevented if the patients started their jaw opening from an increased bite height, eg with cotton rolls inserted bilaterally in the molar region. In both patients, the ADD_R was associated with tenderness of the TMJ and masticatory muscles assessed by reflex responses (ie, blinking or flinching) on the ipsilateral side, elicited by unilateral palpation with firm finger pressure (Table I). EMG-guided diagnostic block of the ipsilateral LP with local anesthetics abolished clicking in both patients for more than 2 days. The maximum unassisted jaw movements (Table I) and translation of the condyles on oblique lateral transcranial radiology (Fig 1) were normal in both patients.

The 2 patients had complete natural dentitions without malocclusions and occlusal support (ICP) on

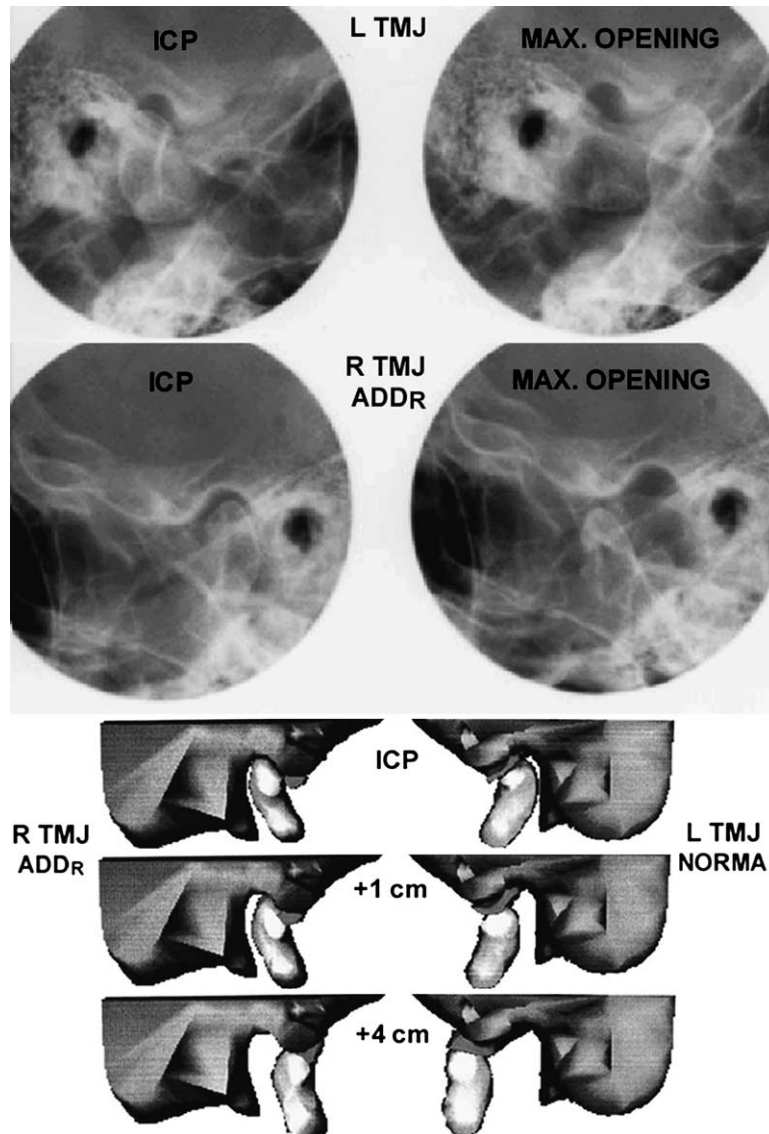


Fig 1. Oblique lateral transcranial radiographs (top) and reconstructed lateral magnetic resonance images (bottom) in occlusion (ICP) and during jaw opening (maximum and with 1 and 4 cm interincisal opening) in Patient 1. The radiographs show normal osseous TMJ structures and condylar translation, and the reconstructed magnetic resonance images demonstrate anterior disc displacement with reduction in the right TMJ and normal disc-condyle relationship in the left TMJ.

molars and premolars. Both patients had been treated for their TMJ condition with conservative measures (eg, splints and jaw exercises) for several years with little effect on their symptoms and they still wore flat-plane, stabilization splints during nighttime.

Methods

The treatment consisted of: (1) an EMG-guided injection of BTX-A (BTX-A 1) into the LP in the same side as the ADDR, (2) another BTX-A injection (BTX-A 2) after 6 months to accentuate or prolong the effect, and (3) withdrawal of splint 6 months after BTX-A 2,

followed by an additional observation time of 6 months. Thus, the patients were followed systematically for 1.5 years after the start of the BTX-A treatment. The treatment effect was assessed by: (1) verbal reports and clinical recordings of clicking and jaw movements, (2) EMG recordings from LP, and (3) MRI of the TMJ.

BTX-A treatment. A commercially available preparation of BTX-A (Botox; Allergan, Irvine, Calif) was reconstituted with 0.9% sterile saline to a concentration of 10 U Botox per 0.1 mL, and 30 U were used for the injection into the ipsilateral LP. The BTX-A was given

Table II. Maximum range of mandibular movements measured before and after unilateral BTX-A treatment (two injections with 30 U Botox with an interval of six months) of the lateral pterygoid muscle in the same side as the TMJ disorder (ADD_R) and measured again at the end of the observation period

Maximum, unassisted jaw movements (mm)	Patient no.	Before BTX-A	After BTX-A treatment (average of measurements from two injections)		End of observation period 1 yr after last BTX-A injection
			1 month	4 months	
Protrusion	1	11	11	10	9
	2	8	7	8	8
Laterotrusion to contralateral side	1	13	8*	9*	12
	2	12	7*	12	10
Laterotrusion to ipsilateral side	1	13	13	13	12
	2	9	10	10	9
Opening	1	54	52	54	56
	2	50	50	48	53

*Exceeding the longitudinal, normal variation of maximum mandibular mobility (largest intraindividual difference: horizontal movements 3 mm, vertical movements 7 mm).³⁷ Normative data (Scandinavian women 18-25 yr (M±SD): protrusion 9.0±1.8 mm, laterotrusion 9.6±1.6 mm, opening 53.3±5.7 mm).³⁶

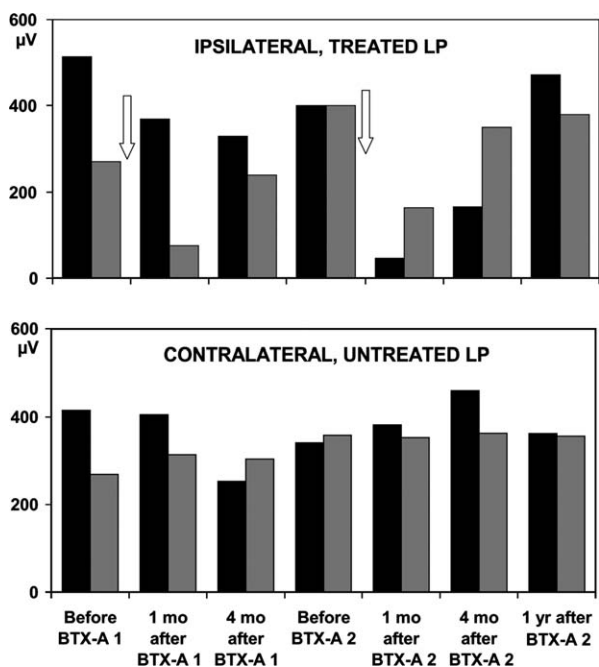


Fig 2. Levels of maximum EMG activity (MVC) in the lateral pterygoid muscle (LP) during contralateral jaw movement against resistance. Top, the levels of activity in the injected LP, ipsilateral to the disc displacement with reduction before and 1 and 4 months after first and second injections with botulinum toxin (BTX-A 1 and BTX-A 2) and at the end of observation period 1 yr after BTX-A 2; bottom, the corresponding levels in the contralateral, untreated LP. Arrows indicate time of BTX-A 1 and BTX-A 2. Black columns represent the levels in Patient 1, gray columns the levels in Patient 2. The activity levels in the treated LP were temporarily reduced after BTX-A treatment, most markedly in the recordings 1 month after BTX-A, and the levels were restored again in the recordings before BTX-A 2 (0.5 yr after BTX-A 1) and 1 yr after BTX-A 2. No systematic changes were seen in the untreated LP.

as bolus injection through a monopolar cannulated electrode (50 × 0.45 mm; Medtronic, Skovlunde, Denmark) for simultaneous recording and EMG guidance. The BTX-A treatment was repeated after 6 months and was not associated with adverse effects such as dysphagia.

The LP was approached intraorally, lateral to the maxillary tuberosity (ie, halfway between the muscle origin and insertion), with the needle just above the maxillary molars and parallel to the occlusal plane.¹² The injection site was located by EMG (Counterpoint; Medtronic; standard procedures: sample frequency 51.2 kHz, 1 s time window, gain ×1,000-10,000, lower limiting frequency 20 Hz, and upper limiting frequency 5 kHz), verifying that maximum level of activity was obtained during contralateral jaw movement against resistance. No effort was made to differentiate between the lower and upper head of the LP. No dystonic activity during rest, ie, more than 100 turns/s with the amplitude above 100 μV,³³ could be recorded.

Verbal reports and recording of clicking and jaw movements. The clinical examination, before and 1 and 4 months after both BTX-A injections, and again 1 year after BTX-A 2, included standard questions regarding the ADD_R and associated symptoms. The TMJ clicking was assessed by stethoscope and by palpation during vertical and horizontal jaw movements and during chewing of gum, and also by direct auscultation when lifting the jaw at the mandibular basis during open-close movements. Maximum unassisted protrusion, laterotrusion, and jaw opening were measured in mm at the central incisors as the largest of 3 measurements, taking into account the overjet, the midline deviation, and the overbite, respectively.

EMG. For evaluation of the BTX-A effect, the activity of LP during maximum voluntary contractions

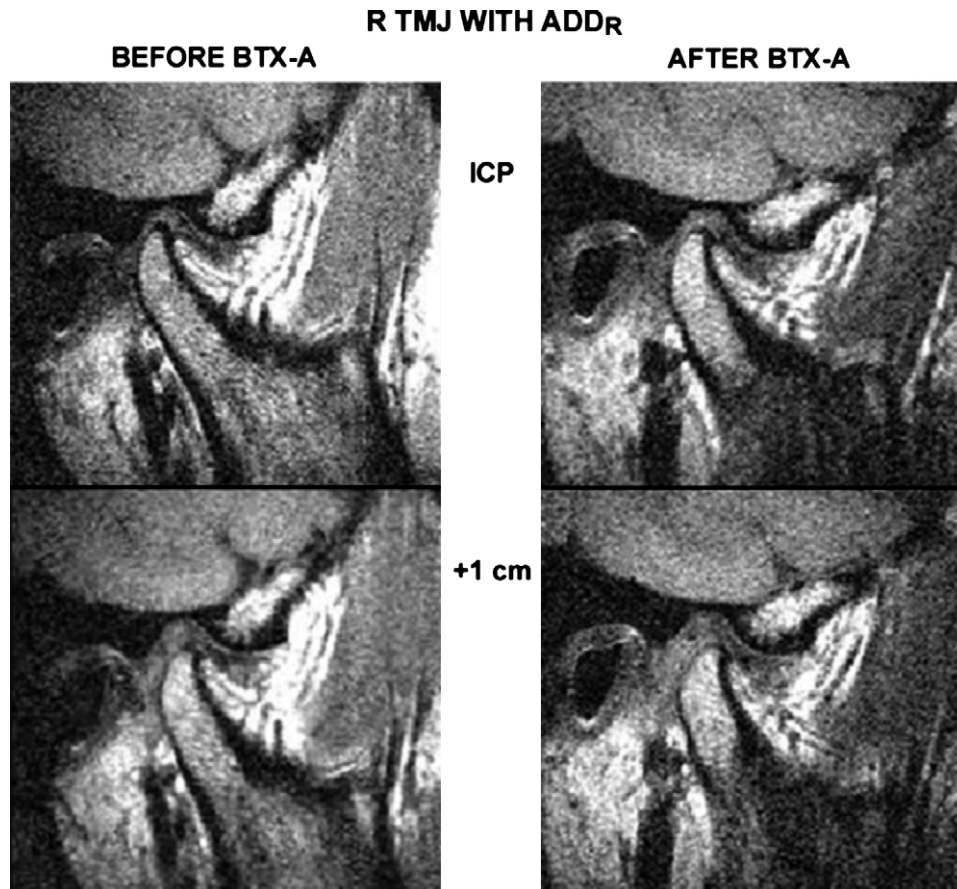


Fig 3. Lateral magnetic resonance imaging in Patient 1 with anterior disc displacement with reduction in the right TMJ before and after treatment with botulinum toxin (BTX-A) with the teeth in occlusion (ICP) and with 1 cm interincisal opening. After treatment the disc displacement changed from a mild to a slight anterior displacement and the TMJ clicking ceased.

(MVC), ie, contralateral jaw movement against resistance (average level of the mean rectified voltage), was recorded (Nicolet Viking 1.7; Nicolet, Madison, Wis; and CMN program; Judex, Aalborg, Denmark; sample frequency 2.5 kHz, gain $\times 100$ -200.000, lower limiting frequency 30 Hz, and upper limiting frequency 1 kHz) on both sides, before and 1 and 4 months after both BTX-A injections, and again 1 year after BTX-A 2. The electrical activity was picked up by means of disposable concentric needle electrodes (50 mm \times 0.46 mm; Medtronic, Skovlunde, Denmark). The LP was approached and the needle electrode was inserted as described above regarding BTX-A treatment. Besides placing the needle in the site of obtaining the maximum level of activity, no effort was made to differentiate between the lower and upper head of LP. LP activity during rest and activities of the temporalis, masseter, and digastric muscles were also recorded, but these data are not included in the present report.

MRI. TMJ images were obtained before BTX-A 1 and 0.5-1 year after BTX-A 2 in the oblique sagittal plane

perpendicular to the transverse axis of the mandibular condyle, in occlusion (ICP) and with 1, 2, 3, and 4 cm interincisal distance, using a 1.5T MR scanner (Magnetom Vision; Siemens, Erlangen, Germany) with bilateral surface coils.³⁴ The slice thickness was 2.0 mm and the slice gap 0.2 mm. Scanning parameters included a TR of 456 ms, a TE of 20 ms, and a T1-weighted spin-echo sequence. Scanning time for each joint was 3 minutes. The anterior disc displacement was diagnosed with the jaw closed (ICP) in the sagittal plane, by using the position of the posterior band of the disc as a discriminator, and classified according to Draz and Enzmann³⁵ in terms of the number of degrees from a 12 o'clock or vertical position relative to the mandibular condyle. A line was drawn through the summit points of the postglenoid tubercle and articular eminence with the marking of the midpoint of the condylar portion, and the angle was measured between the perpendicular on this line through the midpoint of the condyle and the line through the posterior margin of the disc and the midpoint. The data were also

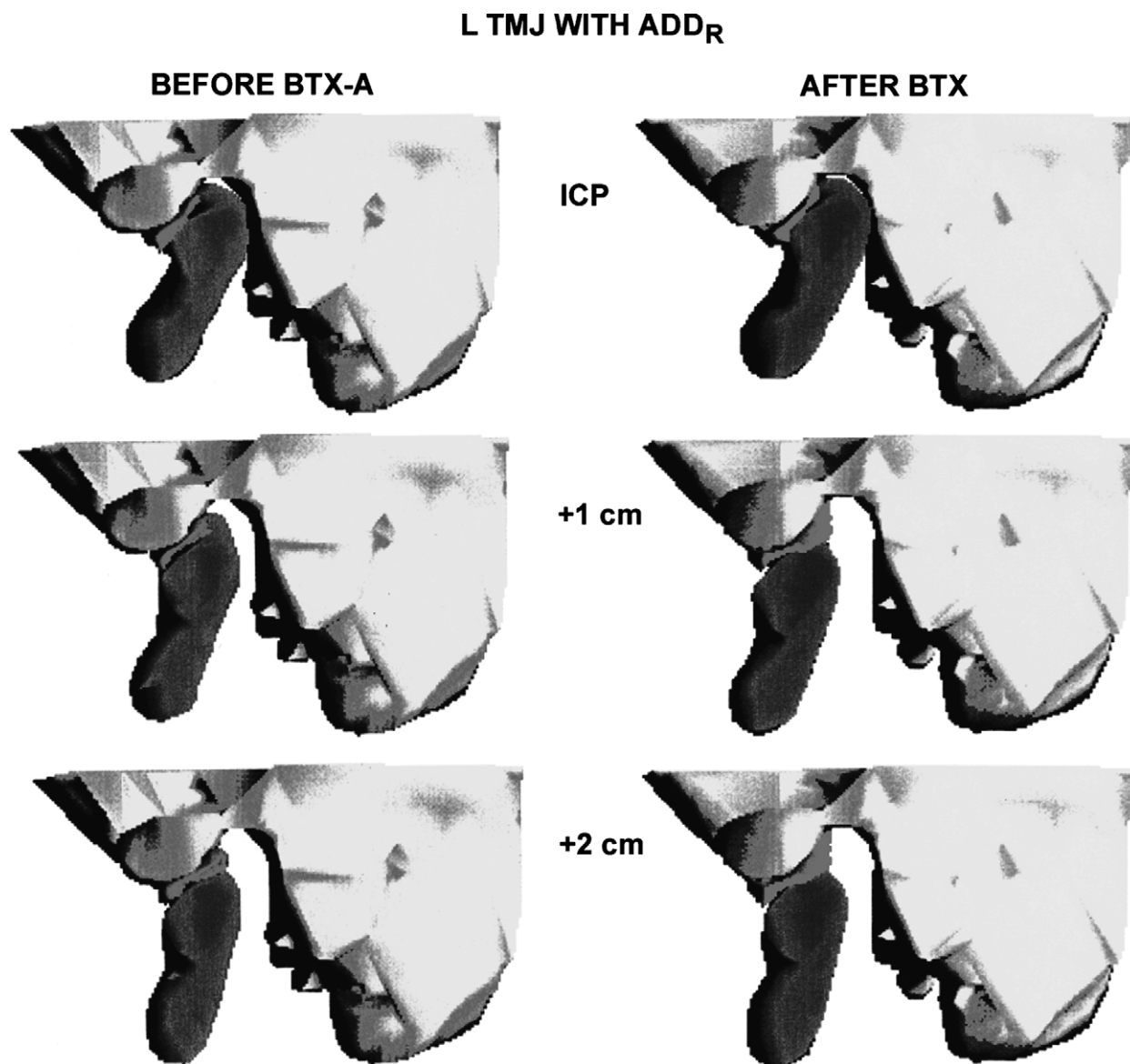


Fig 4. Reconstructed sagittal magnetic resonance images of the left TMJ in Patient 2 with the teeth in occlusion (ICP) and with 1 and 2 cm interincisal opening. To the left, the images before treatment (before BTX-A) show mild anterior disc displacement with reduction, and to the right the images after treatment (after BTX-A), where TMJ clicking had disappeared, show slight displacement.

transferred to a graphic computer (Silicon Graphics, Mountainview, Calif) and registered according to structures in the temporal region (Analyse; Analyse-Direct, Lenexa, Kan), and the mandibular condyle, the glenoid fossa, and the articular disc were segmented and reconstructed 3-dimensionally (Mvox; Anamedic, Copenhagen, Denmark).

RESULTS

Symptoms and signs

In Patient 1, clicking and earache ceased after BTX-A 1, but a sensation of blockage or “stuffed” feeling

of the ipsilateral ear remained. At control after BTX-A 2, the clicking had not returned and the stuffed feeling was diminished, and at control 1 year after BTX-A 2 all symptoms and signs were gone. In Patient 2, clicking and catching ceased after BTX-A 1. No recurrence was present at control after BTX-A 2, and at control 1 year after BTX-A 2 no symptoms and signs were present. The withdrawal of the splint did not influence symptoms and signs in either of the patients.

Before treatment, maximum jaw movements fitted with normative data (Table II).³⁶ The BTX-A injections into the ipsilateral LP temporarily reduced the laterotrusion to

the contralateral side in both patients (Table II).^{36,37} No changes were seen in the jaw opening capacity or during protrusion and ipsilateral laterotrusion (Table II).

EMG activity of LP

Before treatment the maximum level of the LP did not deviate from reference values from healthy subjects (Electromyographic Laboratory, Clinical Oral Physiology, School of Dentistry, University of Copenhagen). There was a systematic decrease of the maximum activity of the injected, ipsilateral LP (Fig 2), which was most marked 1 month after the BTX-A injections (median difference -66%, range -89% to -28%), and no systematic variation was present in the contralateral LP (median difference +4%, range -2% to +17%). At control 1 year after BTX-A 2 no decrease from the BTX-A was present in the injected, ipsilateral LP (median difference +16%, range -8% to +40%) or in the contralateral, untreated LP (median difference +11%, range -10% to +32%).

Disc displacement on MRI

Before treatment, the anterior disc displacement was complete and was classified as mild anterior disc displacement (31-50 degrees) in both patients (Figs 1, 3, and 4), and the disc-condyle relationship was normal in the contralateral side (0-10 degrees).³⁵ The displacement was reduced relative to the condyle with an interincisal distance of 1-2 cm, and no obvious disc deformities were present. After BTX-A treatment, MRI showed slight but distinct improvement in the disc-condyle relationship in the TMJ with ADD_R (Figs 3 and 4), but a slight disc displacement was still present (11-30 degrees) which was clearly reduced at an interincisal distance of 1 cm.

DISCUSSION

The report introduces a novel treatment procedure, using BTX-A in patients with severe TMJ clicking associated with AAD_R. BTX-A injections are considered a safe and efficient local treatment in focal dystonia and muscle spasms.³⁸ In the present study, with normal levels of LP activity, moderate dosages of BTX-A, injected with EMG guidance to ensure correct delivery, provided transient chemodenervation and reduced function of the LP, shown by EMG and clinical recordings, without any adverse effects. In addition, the BTX-A blocking of gamma motor neurons to the muscle spindles in the LP may have temporarily changed the kinetic information and the feedback to the alpha motor neurons^{39,40} as well as modulated arthrokinetic reflexes.^{41,42} Already following the first BTX-A injection symptoms and signs from the AAD_R

were eliminated, but another BTX-A injection was given to accentuate or prolong the effect.

Earlier studies, quoted in the introduction, suggest that displacement of the articular disc may be caused, precipitated, or maintained by LP activity or friction between the articular surfaces of the disc and condyle. The LP activity before BTX-A treatment corresponded to reference values, and no recurrence of TMJ symptoms and signs were observed after the LP activity was restored to normal again. However, owing to the effect of the BTX-A on the LP, contralateral movements of the condyle were diminished for a long period, although ipsilateral and protrusive movements were unchanged. A limitation in the lateromedial direction may reduce the corresponding tractional forces produced during jaw function and perhaps favor regenerative processes.^{43,44} The effect of such limitation is, however, speculative, such as the effect of the possibly changed kinetic information and arthrokinetic reflexes. However, the small but distinct permanent positional improvement in the disc-condyle relationship shown on MRI 0.5-1 year after the last BTX-A injection (ie, when the effect of the BTX-A on the LP was gone), might in itself be important for the elimination of the clicking. As slight reducing disc displacements may be seen in asymptomatic subjects,^{45,46} the disc displacement in the 2 patients may have changed from a symptom-producing ADD_R to a silent ADD_R. However, the precise mechanisms behind the favourable treatment outcome are unclear.

REFERENCES

1. Elfving L, Helkimo M, Magnusson T. Prevalence of different temporomandibular sounds, with emphasis on disc-displacement, in patients with temporomandibular disorders and controls. *Swed Dent J* 2002;26:9-19.
2. Lundh H, Westesson PL. Clinical signs of temporomandibular joint internal derangement in adults. An epidemiologic study. *Oral Surg Oral Med Oral Pathol Oral Radiol Endod* 1991;72:637-41.
3. de Bont LG, Stegenga B. Pathology of temporomandibular joint internal derangement and osteoarthritis. *Int J Oral Maxillofac Surg* 1993;22:71-4.
4. Larheim TA, Westesson PL, Sano T. Temporomandibular joint disk displacement: comparison in asymptomatic volunteers and patients. *Radiology* 2001;218:428-32.
5. Luder HU. Factors affecting degeneration in human temporomandibular joints as assessed histologically. *Eur J Oral Sci* 2002;110:106-13.
6. Milam SB. Articular disk displacements and degenerative temporomandibular joint disease. In: Sessle BJ, Bryant PS, Dionne RA, editors. *Temporomandibular disorders and related pain conditions. Progress in pain research and management*, vol. 4. Seattle: IASP Press; 1995. p. 89-112.
7. Sato S, Goto S, Nasu F, Motegi K. Natural course of disc displacement with reduction of the temporomandibular joint: changes in clinical signs and symptoms. *J Oral Maxillofac Surg* 2003;61:32-4.
8. Eberhard D, Bantleon HP, Steger W. The efficacy of anterior repositioning splint therapy studied by magnetic resonance imaging. *Eur J Orthod* 2002;24:343-53.

9. Reston JT, Turkelson CM. Meta-analysis of surgical treatment for temporomandibular articular disorders. *J Oral Maxillofac Surg* 2003;61:3-10.
10. Yoda T, Sakamoto I, Imai H, Honma Y, Shinjo Y, Takano A, et al. A randomized controlled trial of therapeutic exercise for clicking due to disk anterior displacement with reduction in the temporomandibular joint. *Cranio* 2003;21:10-6.
11. Vichaichalmvong S, Nilner M, Panmekiate S, Petersson A. Clinical follow-up with different disc positions. *J Orofac Pain* 1993;7:61-7.
12. Møller E. The chewing apparatus. An electromyographic study of the action of the muscles of mastication and its correlation to facial morphology. *Acta Physiol Scand* 1966;69(suppl 280): 1-229.
13. Bertilsson O, Ström D. A literature survey of a hundred years of anatomic and functional lateral pterygoid muscle research. *J Orofac Pain* 1995;9:17-23.
14. Murray GM, Phanachet I, Ushida S, Whittle T. The role of the human lateral pterygoid muscle in the control of horizontal jaw movements. *J Orofac Pain* 2001;15:279-305.
15. Fujita S, Iizuka T, Dauber W. Variation of heads of lateral pterygoid muscle and morphology of articular disc of the human temporomandibular joint—anatomical and histological analysis. *J Oral Rehabil* 2001;28:560-71.
16. Naidoo LC. Lateral pterygoid muscle and its relationship to the meniscus of the temporomandibular joint. *Oral Surg Oral Med Oral Pathol Oral Radiol Endod* 1996;82:4-9.
17. Wongwatana S, Kronman JH, Clark RE, Kabani S, Mehta N. Anatomic basis for disk displacement in temporomandibular joint (TMJ) dysfunction. *Am J Orthod Dentofacial Orthop* 1994; 105:257-64.
18. Juniper RP. Temporomandibular joint dysfunction: a theory based upon electromyographic studies of the lateral pterygoid muscle. *Br J Oral Maxillofac Surg* 1984;22:1-8.
19. Liu ZJ, Wang HY, Pu WY. A comparative electromyographic study of the lateral pterygoid muscle and arthrography in patients with temporomandibular joint disturbance syndrome sounds. *J Prosthet Dent* 1989;62:229-33.
20. Brin MF. Botulinum toxin therapy: basic science and overview of other therapeutic applications. In: Blitzer A, editor. *Management of facial lines and wrinkles*. Philadelphia: Lippincott, Williams and Wilkins; 2000. p. 279-302.
21. Capra NF, Bernanke JM, Porter JD. Ultrastructural changes in the masseter muscle of macaca fascicularis resulting from intramuscular injections of botulinum toxin type A. *Arch Oral Biol* 1991;36:827-36.
22. Brin MF. Botulinum toxin: chemistry, pharmacology, toxicity, and immunology. *Muscle Nerve* 1997;20(suppl 6):S146-68.
23. Titner R, Jankovic J. Botulinum toxin type A in the management of oromandibular dystonia and bruxism. In: Brin MF, Hallett M, Jankovic J, editors. *Scientific and therapeutic aspects of botulinum toxin*. Philadelphia: Lippincott, Williams and Wilkins; 2002. p. 343-56.
24. Daelen B, Thorwirth V, Koch A. Treatment of recurrent dislocation of the temporomandibular joint with type A botulinum toxin. *Int J Oral Maxillofac Surg* 1997;26:458-60.
25. Moore AP, Wood CG. Medical treatment of recurrent temporomandibular joint dislocation using botulinum toxin A. *Br Dent J* 1997;183:415-7.
26. Ziegler CM, Haag C, Mühling J. Treatment of recurrent temporomandibular joint dislocation with intramuscular botulinum toxin injections. *Clin Oral Invest* 2003;7:52-5.
27. Bakke M, Werdelin LM, Dalager T, Fuglsang-Frederiksen A, Prytz S, Møller E. Reduced jaw opening from paradoxical activity of mandibular elevator muscles treated with botulinum toxin. *Eur J Neurol* 2003;10:695-9.
28. Spillane KS, Shelton JE, Hasty MF. Stroke-induced trismus in a pediatric patient: Long-term resolution with botulinum toxin A. *Am J Phys Med Rehabil* 2003;82:485-8.
29. von Lindern JJ, Niederhagen B, Berge S, Appel T. Type A botulinum toxin in the treatment of chronic facial pain associated with masticatory hyperactivity. *J Oral Maxillofac Surg* 2003;61:774-8.
30. Freund B, Schwartz M. Intramuscular injection of botulinum toxin as an adjunct to arthrocentesis of the temporomandibular joint: preliminary observations. *Br J Oral Maxillofac Surg* 2003; 41:351-2.
31. Freund B, Schwartz M. Temporal relationship of muscle weakness and pain reduction in subjects treated with botulinum toxin A. *J Pain* 2003;4:159-65.
32. Okeson JP. Orofacial pain. Guidelines for assessment, diagnosis, and management. The American Academy of Orofacial Pain. Chicago: Quintessence; 1996. p. 127-37.
33. Østergaard L, Fuglsang-Frederiksen A, Sjö O, Werdelin L, Winkel H. Quantitative EMG in cervical dystonia. *Electromyogr Clin Neurophysiol* 1996;36:179-85.
34. Kitai N, Kreiborg S, Murakami S, Bakke M, Møller E, Darvann TA, et al. A three-dimensional method of visualizing the temporomandibular joint based on magnetic resonance imaging in a case of juvenile chronic arthritis. *Int J Paediatr Dent* 2002;12:109-15.
35. Drace JE, Enzmann DR. Defining the normal temporomandibular joint: closed, partially open and open mouth MR imaging of asymptomatic subjects. *Radiology* 1990;177:67-71.
36. Agerberg G. Maximal mandibular movements in young men and women. *Sven Tandlak Tidsskr* 1974;67:81-100.
37. Agerberg G. Longitudinal variation of maximal mandibular mobility: an intraindividual study. *J Prosthet Dent* 1987;58:370-3.
38. Jankovic J, Schwartz K, Donovan DT. Botulinum toxin treatment of cranial-cervical dystonia, spasmodic dysphonia, other focal dystonias and hemifacial spasm. *J Neurol Neurosurg Psychiatry* 1990;53:633-9.
39. Kubota K, Masegi T. Muscle spindle supply to the human jaw muscle. *J Dent Res* 1977;56:901-9.
40. Christensen LV, Troest T. Clinical kinesthetic experiments on the lateral pterygoid muscle and temporomandibular joint in man. *Scand J Dent Res* 1975;83:238-44.
41. Clark RK, Wyke BD. Temporomandibular articular reflex control of the mandibular musculature. *Int Dent J* 1975;25: 289-96.
42. Isberg A, Widmalm SE, Ivarsson R. Clinical, radiographic, and electromyographic study of patients with internal derangement of the temporomandibular joint. *Am J Orthod* 1985;88:453-60.
43. Buschang PH, Throckmorton GS, Travers KH, Hayasaki H. Incisor and mandibular condylar movements of young females during maximum protrusion and lateratrusion of the jaw. *Arch Oral Biol* 2001;46:39-48.
44. Gallo LM, Nickel JC, Iwasaki LP, Palla S. Stress-field translation in the healthy human temporomandibular joint. *J Dent Res* 2000; 79:1740-6.
45. Tanaka E, Rodrigo DP, Miyawaki Y, Lee K, Yamaguchi K, Tanne K. Stress distribution in the temporomandibular joint affected by anterior disc displacement: a three-dimensional analytic approach with the finite-element method. *J Oral Rehabil* 2000;27:754-9.
46. Tanaka E, van Eijden T. Biomechanical behaviour of the temporomandibular joint disc. *Crit Rev Oral Biol Med* 2003; 14:138-50.

Reprint requests:

Merete Bakke, DDS, PhD, Dr Odont
 Section of Clinical Oral Physiology
 Department of Oral Medicine, Clinical Oral Physiology, Oral
 Pathology & Anatomy School of Dentistry
 University of Copenhagen
 20 Nørre Allé, DK-2200 Copenhagen N, Denmark
 mb@odont.ku.dk