

Treatment of Temporomandibular Disorders with Botulinum Toxin

Marvin Schwartz, B.Sc., D.D.S., M.Sc., and Brian Freund, B.Sc., D.D.S., M.D., F.R.C.P.C.

The Crown Institute, Toronto, Ontario, Canada

Abstract:

Temporomandibular disorder (TMD) is a collective term used to characterize a heterogeneous group of conditions involving the temporomandibular joint (TMJ) and its contiguous tissues. Although the pathologies behind TMDs have not been completely explained, the symptoms associated with these disorders are similar and are most commonly manifest as pain in the orofacial region. In preliminary studies, botulinum toxin has been used successfully to treat various pain syndromes, including TMDs. Because of the complex nature of TMDs and proximity of affected muscles to facial nerves, correct injection technique and appropriate dosing guidelines are very important for successful results. This article describes common TMDs and their treatment with botulinum toxin. Dosing guidelines and illustrations of affected muscles and target injection sites are provided.

Key Words: Temporomandibular disorders—Temporomandibular joint—Orofacial pain—Botulinum toxin

The temporomandibular joint (TMJ) connects the mandible with the temporal bone of the skull (Fig. 1). This joint serves many functional purposes, chief among them being deglutition, speech, and breathing. Temporomandibular disorder (TMD) is a collective term used to describe a group of pathologic conditions affecting the TMJ, its associated structures, and its functions. Included in the TMDs are a wide variety of medical disorders of orthopedic and myofascial origin that closely resemble those described for other joint and muscle conditions. Because the TMJ is one of the body's most active, essential, and intensely loaded joints, the significance of dysfunction of the muscles responsible for TMJ function and resultant pathology is critical. The unique nature of TMD resides in the proximate anatomy of many other facial and cranial structures that complicate, interact with, and mimic other sources of head and neck pain.

Symptoms commonly associated with TMDs include the following: difficulty speaking, eating, and sleeping; chronic headaches; earaches or hearing impairment; jaw dysfunction, including hyper- and hypomobility; and general orofacial pain. Pain, particularly at the TMJ, is the most common symptom.

Epidemiologic data on TMDs are inadequate due to the heterogeneity of symptoms and absence of clear guidelines for diagnosis. However, combined results from a nationwide survey and a meta-analysis of 51 TMD prevalence studies, De Kanter et al.¹ arrived at a perceived dysfunction rate of 30% in a general population of more than 15,000 persons (23 studies) and a professionally assessed dysfunction in 44% of more than 16,000 persons (22 studies). In a review of access to health-care, 20% to 25% of the population seeks professional care for symptoms of TMD at some point.^{2,3} Advanced care requiring the expertise of specialists was required in 5% to 10% of the population.⁴ Although the statistics may not be precise, largely due to a lack of uniformity in classification, it is clear that TMDs are common in nonpatient populations.⁵ The economic and societal costs are substantial.^{6,7}

Address correspondence to Dr. Marvin Schwartz, 321 Sheppard Avenue East, Toronto, Ontario, Canada M2N 3B3; e-mail: Schwartz@CrownInstitute.com

Publication of this supplement was supported by an unrestricted educational grant from Elan Pharmaceuticals, Inc.

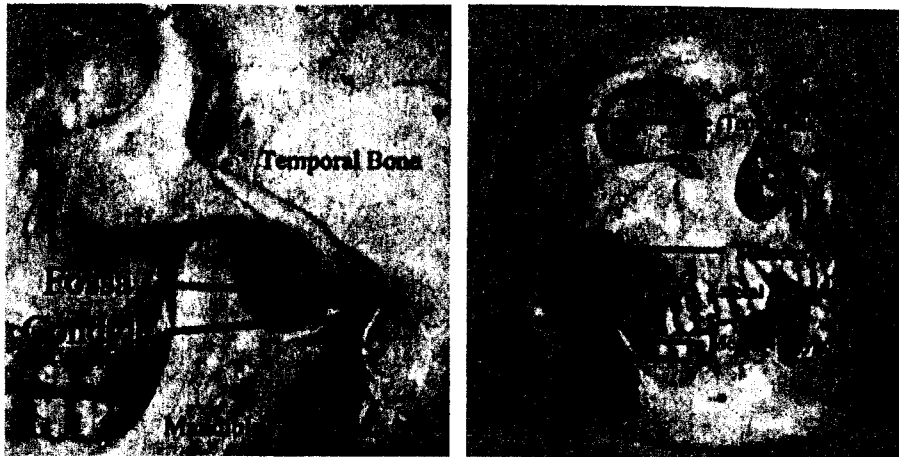


FIG. 1. The temporomandibular joint and associated musculature. The temporomandibular joint (TMJ) connects the mandible with the temporal bone of the skull. Temporomandibular disorder (TMD) is a collective term used to describe a group of pathologic conditions affecting the TMJ, its associated structures, and its functions.

Differential diagnosis for TMD is complex because of its nonspecific etiologies and the diverse nature of conditions that are applicable to almost all head and neck pain. Although a universally accepted taxonomy is unavailable, an overview of this subject presented by Ohrbach and Stohler⁸ reveals an important and clear theme within most systems. The theme bases proper TMD diagnosis on the determination of pathology using an anatomic and functional etiology with two critical areas requiring thorough assessment: (1) pathology originating in the TMJ or intracapsular pathology (arthrogenic) and (2) pathology originating in the musculature (myogenic). The two, of course, are interdependent, requiring concurrent assessment and, often, concurrent care.

BOTULINUM TOXIN FOR TEMPOROMANDIBULAR DISORDER

Prospective, randomized clinical studies have demonstrated the effectiveness of using a biologic neuromuscular blocking agent, botulinum toxin, for the treatment of neurologic disorders associated with hyperactivity of skeletal muscles.^{9,10} Although originally indicated for treating focal dystonias, botulinum toxin also has been demonstrated to provide pain relief in the head (migraine, tension headaches) and neck (cervical dystonia, whiplash-associated neck pain), suggesting its potential role in the treatment of TMDs.¹⁰⁻¹³ The diverse group of TMDs involving the orofacial musculature that have shown early evidence of being amenable to treatment with botulinum toxin include the following: (1) bruxism and clenching; (2) oromandibular dystonias; (3) myofascial pain (often due to parafunction); (4) myofascial pain with secondary TMJ involvement; (5) trismus; (6) hypermobility; (7) masseter and temporalis hypertrophy; and (8) headaches.

Bruxism

Various forms of bruxism have been described, and current treatment of bruxism is therefore neither uniform nor universally successful. Bruxism can affect the muscles solely or can act as a parafunction that is an initiating and/or perpetuating factor in more involved forms of TMD involving joint damage. Many characteristics of bruxism mimic those of dystonia, including similar epidemiology, pain, and exacerbation by external factors such as fatigue, stress, and emotional extremes. Watts et al.¹⁴ have suggested that bruxism may itself be a form of dystonia. If bruxism is a type of dystonia, it is possible that success of the most common treatment of bruxism with intraoral appliances or occlusal adjustments may simply be a "sensory trick" that relieves dystonic symptoms. However, given the similarities between TMD and dystonia, successful use of botulinum toxin for bruxism has been described, and botulinum toxin will probably become an important tool for treatment.

Oromandibular dystonia

This subset of movement disorders is categorized as a focal dystonia that involves the musculature of the masticatory apparatus and lower face. It manifests as distorted oral position and function, resulting in orofacial disfigurement and dysfunction. Although it is commonly viewed as a neurologic disorder, there is no doubt of its inclusion as a subset of TMDs owing to the involvement of the masticatory apparatus. Successful treatment with botulinum toxin has been demonstrated.¹⁵ Even more significantly, early evidence of pain relief with botulinum toxin in the treatment of oromandibular dystonia has been reported.¹⁶

Myofascial pain

There has been little evidence of muscle hyperactivity in the most common cases of TMD involving facial pain

with or without joint involvement. However, muscle relaxation using physical and pharmacologic therapies has been successful in the treatment of the pain. Previous work published by the authors demonstrates that a reduction in bite strength concomitant with botulinum toxin results in pain relief.¹⁶ In fact, the pain relief outlasts the weakening of the muscles treated. Botulinum toxin therapy can alleviate pain of myofascial origin and, indirectly, pain of arthrogenic origin. The latter is achieved with the prolonged "joint-sparing" effect of diminished loading secondary to the decreased ability of the musculature to effect joint loading.

Masseter and temporalis hypertrophy

Masseter and temporalis hypertrophy is largely regarded as a cosmetic facial deformity based on excess muscle bulk. Muscle overactivity also may occur. Injection with botulinum toxin has been shown to produce sustained atrophy and reduce muscle bulk.¹⁷

Tension headaches

Most tension headaches involve the temporalis and/or masseter muscles. There is no distinction between the classification of this clinical phenomenon as a myogenous TMD versus a tension headache. Indeed, Jensen¹⁸ has proposed temporalis muscle pain induced by tooth clenching as a valuable experimental model for tension headache. Several small studies have demonstrated that

treatment of tension headache with botulinum toxin type A is effective.¹⁹⁻²⁵ Studies with botulinum toxin type B in tension headaches are under way.

INJECTION TECHNIQUE FOR BOTULINUM TOXIN

A thorough knowledge of the underlying anatomy of the muscles that may be involved in TMD is essential for both diagnosis and treatment. For simplicity, the muscles can be grouped as follows:

Jaw-closing muscles: temporalis, masseter, medial pterygoid

Jaw-opening muscles: suprahyoids, lateral pterygoid

Significant muscles of the neck: sternocleidomastoid, trapezius, paracervical musculature

Significant muscles of the cranium and face: frontalis, occipitalis, procerus, corrugator

The latter two are considered significant because of their indirect but supportive role in jaw function and their frequent association with TMD. An anatomic summary of the significant masticatory muscles and dose ranges of botulinum toxin is presented in Table 1. Individual injection techniques are outlined below.

Temporalis

The temporalis muscle is readily accessible superficially in the temple area. It is a fan-shaped muscle of

TABLE 1. Masticatory muscles and dose ranges of botulinum toxin

Muscle	Origin	Insertion	Type A (Botox)		Type B (Myobloc)	
			Dose (units)*	Number of injections	Dose (units)†	Number of injections
Temporalis	Temporal fossa	Medial and anterior aspect of coronoid process of mandible	5-25 U	5	1,000-3,000 U	2-4/side
Masseter	Anterior two thirds of zygomatic arch and zygomatic process of maxilla	Lateral surface of angle and lower ramus of mandible	25-50 U	5	1,000-3,000 U	2/side
Medial pterygoid	Deep head medial side of lateral pterygoid plate and fossa between medial and lateral plates. Superficial head: tuberosity of maxilla and pyramidal process of palatine bone	Medial aspect of angle of mandible	5-25 U	2-3	1,000-3,000 U	1/side
Lateral pterygoid	Upper head: infratemporal surface of sphenoid bone. Lower head: lateral surface of lateral pterygoid plate	Pterygoid fovea below condyloid process of mandible and TMJ meniscus	5-10 U	1	1,000-3,000 U	1/side

*All injections with dilution of 5 U per 0.1 ml except for masseter at 10 U per 0.1 ml. (Botox: Allergan, Inc., Irvine, CA).

†Dosage recommendations for Myobloc (Elan Pharmaceuticals, San Diego, CA) obtained from: WE MOVE. Practical considerations for the clinical use of botulinum toxin type B: a self-study continuing medical education activity. February, 2002.²⁶

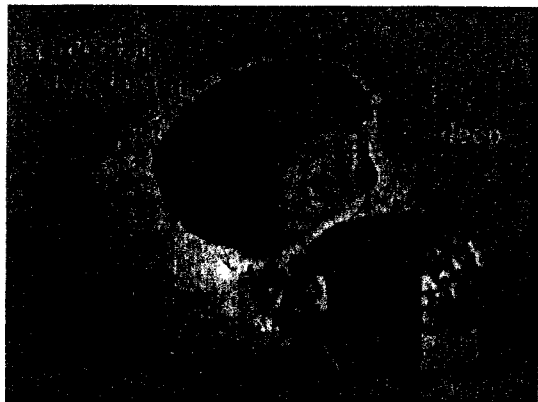

FIG. 2. Injection techniques for the temporalis muscle. Two types of injection are usually used to adequately weaken the temporalis muscle, superficial and deep. Superficial injections are administered into the thinner upper regions of the muscle in a fan shape. A single deep injection can also be administered, as shown, but particular note must be taken of the split of the superficial temporalis fascia approximately 1.5 cm superior to the zygomatic arch. In this area there are two superficial fascia layers with fat in between, whereas the muscle is deeper. If the operator uses the tactile sensation of penetration of the needle through fascia as a guide for injection, two penetrations are necessary in this area.

variable expanse and depth. Two types of injection, superficial and deep, are usually used to adequately weaken this muscle (Fig. 2). Superficial injections are performed into the thinner upper regions of the muscle in a fan shape. No special precautions are required, although advancing the needle too deeply engages bone and damages the needle. The deeper single injection requires special anatomic consideration. For this injection, particular note must be taken of the split of the superficial temporalis fascia approximately 1.5 cm superior to the zygomatic arch. In this area there are two superficial fascia layers with fat in between, whereas the muscle is deeper. If the operator uses the tactile sensation of penetration of the needle through fascia as a guide for injection, two penetrations are necessary in this area. This latter injection is probably very useful because the muscle in this area is the thickest before insertion on the coronoid process of the mandible. Aspiration before injection is critical because large vessels course through this field.

Masseter

The masseter muscle is readily accessible clinically. It is a thick muscle of trapezoidal shape extending from the zygomatic arch superiorly to the lower border of the mandible inferiorly and from the posterior border of the mandibular ramus posteriorly to mid-cheek anteriorly. Approximately five diffuse injections are recommended, preferably targeted to areas of highest activity on electromyography (EMG), greatest muscle bulk, and/or

greatest discomfort (Fig. 3). Care must be taken with anterior and superior injections of this muscle because diffusion of botulinum toxin to the zygomaticus major muscle nearby may result in an adverse cosmetic effect, specifically preventing the patient from raising the corner of the mouth and thus causing an asymmetric smile.

Medial pterygoid

The medial pterygoid muscle lies on the medial surface of the mandible and is somewhat difficult to reach (Fig. 4). The utility of injecting this muscle in most instances is questionable because adequate relaxation of the masseter and temporalis jaw-closing muscles appears to provide enough clinical effect to relieve pain relief and reduce joint loading. The muscle can be injected extra-orally via a submandibular route. However, the angulation does not lend itself to good visibility or easy access to the superior aspect of the muscle. The intraoral approach allows palpation of the muscle before injection except when the patient has a sensitive gag reflex or limitation in oral opening. In either technique, care must be taken to stay within the muscle because superior medial injection can approach the infratemporal fossa and its contents. Branches of the external carotid artery, branches of the trigeminal nerve, and muscles of the pharynx can be adversely affected. Inferior medial injection outside the medial pterygoid can affect the submandibular gland as well as muscles of the floor of the mouth. EMG guidance is therefore required.

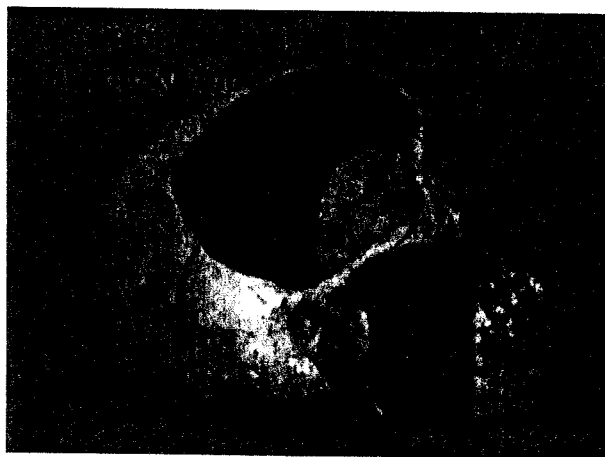

FIG. 3. Injection technique for the masseter muscle. Approximately five diffuse injections into the masseter muscle are recommended, preferably targeted to areas of highest activity on EMG, greatest muscle bulk, and/or greatest discomfort. Care must be taken with anterior and superior injections of this muscle because diffusion of botulinum toxin to the zygomaticus major muscle nearby may prevent the patient from raising the corner of the mouth, causing an asymmetric smile.

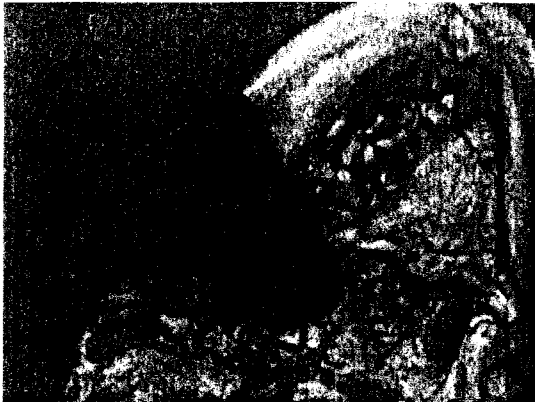

FIG. 4. Medial pterygoid. The utility of injecting this muscle in most instances is questionable because adequate relaxation of the masseter and temporalis jaw-closing muscles appears to provide enough clinical effect to relieve pain and reduce joint loading.

Lateral pterygoid

This small muscle requires EMG guidance for injection because of its size and location (Fig. 5). The approach is operator-dependent, either extra- or intraoral. Using the extraoral route involves establishing the location of the condylar head by palpation as the patient demonstrates a full range of mandibular motion. The needle is inserted through the skin in the coronoid notch area and is advanced at 45° posteriorly to gently engage the condylar head. The needle is then withdrawn slightly and advanced more anteriorly and slightly deeper. The patient is then asked to mobilize the mandible from side to side, and aspiration and injection are performed once proper position is ascertained. The intraoral approach involves access posterior to the maxillary tuberosity in a lateral direction. Once the needle is inserted through mucosa, it is helpful to visualize the patient's ear (knowing

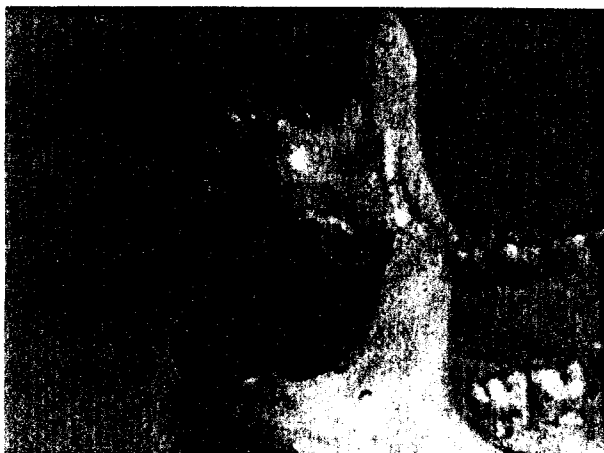

FIG. 5. Lateral pterygoid. This small muscle requires EMG guidance for injection because of size and location. The approach is operator-dependent, either extraoral or intraoral.

that the TMJ is just anterior to the external auditory meatus) to guide the needle laterally and posteriorly. There are variations of these basic techniques. Considerable caution must be taken while injecting in this infratemporal fossa area, as noted previously. It is also important to note that the muscle is surrounded by the pterygoid plexus of veins.

Additional guidelines

Dose: The dose is individualized to the patient and is dependent on muscle size, pain, and activity, as well as other factors. A range of dosing is provided for guidance (Table 1).²⁶

Location of injection within muscle: At this time there is no scientific evidence of superior results when the injections are directed at trigger/tender points or directed diffusely to affect most of a muscle. Many clinicians prefer to inject where there is symptomatology, often referred to as "chasing the pain."

Agonist muscles: Temporalis, masseter, and medial pterygoid are agonist jaw-closing muscles, both ipsilaterally and bilaterally. If all of the muscles are not injected, there is a possibility of compensatory changes in the untreated muscles, which can lead to failure. The medial pterygoid appears to be less affected by this phenomenon and is rarely injected initially.

Needle size: Injections in the face, and particularly into painful musculature, call for the use of a small-gauge needle, preferably 30-gauge. A 27-gauge needle is tolerable for the larger muscles such as the masseter. See the techniques for specific muscles for recommendations for EMG guidance.

Adjunctive anesthesia: Topical local anesthetic, such as EMLA applied before injection, is always helpful. For muscles already in pain, preinjection with local anesthetic and botulinum follow-up is advocated by some. Intravenous sedation or general anesthesia may be needed for patients in considerable pain.

CONCLUSIONS

The personal and societal costs of TMDs are enormous. Current treatment regimens fall short in patient care, partly because of inadequate control of the myofascial component of the disorder. Furthermore, the overlap of TMD with other common primary head and neck pains is significant and requires further elucidation. Botulinum toxin is emerging as a very potent and valuable clinical tool for the diagnostic and therapeutic care of TMD. The success of botulinum toxin therapy forces us to re-examine our understanding of TMDs, their origins, and their relationships to other head and neck pains

and myofascial conditions. Ongoing clinical trials seek to provide a scientific basis for the use of botulinum toxin in TMD. As previously seen in the use of botulinum toxin for other pathologic conditions, the clinical advancement of the science will outpace the path to complete understanding and regulatory approval.

REFERENCES

- De Kanter RJ, Truin GJ, Burgersdijk RC, et al. Prevalence in the Dutch adult population and a meta-analysis of signs and symptoms of temporomandibular disorder. *J Dent Res* 1993;72:1509-18.
- Carlsson GE. Epidemiology and treatment need for temporomandibular disorders. *J Orofac Pain* 1999;13:232-7.
- Carlsson GE, Helkimo M. Epidemiologic studies of mandibular function. *J Prosthet Dent* 1983;50:134-5.
- Israel HA. Temporomandibular disorders: what the neurologist needs to know. *Semin Neurol* 1997;17:355-66.
- Elfving L, Helkimo M, Magnusson T. Prevalence of different temporomandibular joint sounds, with emphasis on disc-displacement, in patients with temporomandibular disorders and controls. *Swed Dent J* 2002;26:9-19.
- Kuttila M, Kuttila S, Le Bell Y, et al. Association between TMD treatment need, sick leaves, and use of health care services for adults. *J Orofac Pain* 1997;11:242-48.
- White BA, Williams LA, Leben JR. Health care utilization and cost among health maintenance organization members with temporomandibular disorders. *J Orofac Pain* 2001;15:158-69.
- Ohrbach R, Stohler CS. Review of the literature: a current diagnostic system. *J Craniomandibular Disord* 1992;6:307-17.
- Brans JW, Lindeboom R, Snoek JW, et al. Botulinum toxin versus trihexyphenidyl in cervical dystonia: a prospective, randomized, double-blind controlled trial. *Neurology* 1996;46:1066-72.
- Lew MF, Brashear A, Factor S. The safety and efficacy of botulinum toxin type B in the treatment of patients with cervical dystonia: summary of three controlled clinical trials. *Neurology* 2000;55(12 suppl 5):S29-35.
- Binder WJ, Brin MF, Blitzer A, et al. Botulinum toxin type A (Botox) for the treatment of migraine headaches: an open-label study. *Otolaryngol Head Neck Surg* 2000;123:669-76.
- Freund B, Schwartz M. Treatment of chronic cervical-associated headache with botulinum toxin A: a pilot study. *Headache* 2000;40:231-6.
- Freund B, Schwartz M. Treatment of whiplash associated with neck pain with botulinum toxin-A: a pilot study. *J Rheumatol* 2000;27:481-4.
- Watts MW, Tan EK, Jankovic J. Bruxism and cranial-cervical dystonia: is there a relationship? *Cranio* 1999;17:196-201.
- Blitzer A, Sulica L. Botulinum toxin: basic science and clinical uses in otolaryngology. *Laryngoscope* 2001;111:218-26.
- Freund B, Schwartz M, Symington JM. Botulinum toxin: a new treatment for temporomandibular disorders. *Br J Oral Maxillofac Surg* 2000;38:466-71.
- To EW, Ahuja AT, Ho WS, et al. A prospective study of the effect of botulinum toxin A on masseteric muscle hypertrophy with ultrasonographic and electromyographic measurement. *Br J Plast Surg* 2001;54:197-200.
- Jensen R. Pathophysiological mechanisms of tension-type headache: a review of epidemiological and experimental studies. *Cephalalgia* 1999;19:602-21.
- Freund BJ, Schwartz M. A focal dystonia model for subsets of chronic tension headache. *Cephalalgia* 2000;20:433 (abstract).
- Porta M. A comparative trial of botulinum toxin A and methylprednisolone for the treatment of tension-type headache. *Curr Rev Pain* 2000;4:31-5.
- Relja M. Treatment of tension-type headache by local injection of botulinum toxin. *Eur J Neurol* 1997;4(suppl 2):S71-3.
- Schulte-Mattler WJ, Wieser T, Zierz S. Treatment of tension-type headache with botulinum toxin: a pilot study. *Eur J Med Res* 1999;4:183-6.
- Smuts JA, Baker MK, Smuts HM, et al. Prophylactic treatment of chronic tension-type headache using botulinum toxin type A. *Eur J Neurol* 1999;6(suppl 4):S99-102.
- Wheeler AH. Botulinum toxin A, adjunctive therapy for refractory headaches associated with pericranial muscle tension. *Headache* 1998;38:468-71.
- Zwart JA, Bovim G, Sand T, et al. Tension headache: botulinum toxin paralysis of temporal muscles. *Headache* 1994;34:458-62.
- WE MOVE. Practical considerations for the clinical use of botulinum toxin type B: a self-study continuing medical education activity. February, 2002.