

**ORIGINAL CONTRIBUTION**

Safety and efficacy of a novel high-intensity focused electromagnetic technology device for noninvasive abdominal body shaping

Carolyn I. Jacob MD¹ | Katya Paskova MD²¹Chicago Cosmetic Surgery and Dermatology, Chicago, Illinois²Derma Vita Clinic, Sofia, Bulgaria**Correspondence**Carolyn I. Jacob, Chicago Cosmetic Surgery and Dermatology, Chicago, IL.
Email: cjacob@chicagodermatology.com**Abstract****Background:** Thermal fat reduction technologies are leading the market for non-surgical abdominal contouring. However, they are ideal principally for patients with fat bulges.**Objectives:** Our study investigates the effects of a novel nonthermal technology affecting the abdominal musculature and subcutaneous adipose tissue.**Materials and Methods:** A total of 22 patients (avg. BMI 23.8 kg m⁻²) underwent 4 treatments on abdomen with high-intensity focused electromagnetic (HIFEM) field device. Treatments took 30 minutes and were spaced apart by 2-3 days. Photographs, weight, and waist measurements were taken at the baseline, after the last treatment, and at month 3 follow-up. Patient satisfaction was noted. Photographs were evaluated by blinded evaluators.**Results:** The study protocol was completed by 19 patients. At month 3, the average waist size reduction was 4.37 ± 2.63 cm (*P* < 0.01). The evaluators identified the before image from the 3-month image 89.47% of the time. About 91% of patients reported their abdominal appearance improved, and 92% stated they are satisfied with treatment results at month 3. No adverse events occurred.**Conclusion:** Observed waist size reduction and aesthetic improvement appear to be a combination of fat reduction and increased muscle definition of abdominal wall. In lower BMI patients, the increased abdominal muscle definition was largely responsible for the improvement. This novel energy device provides an additional tool for body contouring with primary application for lower and medium BMI patients.**KEYWORDS**

body, contouring, electromagnetic, HIFEM, muscle, toning

1 | INTRODUCTION

The media-driven images of thin and muscular bodies lead to a high dissatisfaction rate of nonideal body type patients which may result in chronic depression.¹ Currently, up to 60.7% of men and 71.6% of women in US population are dissatisfied with their body size.² The desire for an easy solution to reduce fat and to improve the

appearance of the abdomen is driving the market for body shaping procedures.

In 2017, liposuction was the most common surgical cosmetic procedure, after breast augmentation, with over 300 000 conducted procedures that year.³ Due to the risk of complications (eg, infection, scarring or hematoma⁴), related downtime and substantial financial

This is an open access article under the terms of the Creative Commons Attribution-NonCommercial-NoDerivs License, which permits use and distribution in any medium, provided the original work is properly cited, the use is non-commercial and no modifications or adaptations are made.

© 2018 The Authors. *Journal of Cosmetic Dermatology* Published by Wiley Periodicals, Inc.

cost associated with surgical procedures, there has been a rapid increase in the demand for noninvasive solutions. Since 2012, noninvasive procedures have grown by 217.3%.³ The leading technologies in the noninvasive body shaping are low-level laser therapy (LLLT), cryolipolysis, radio frequency (RF), and high-intensity focused ultrasound (HIFU).⁵

Surgical as well as noninvasive body shaping procedures are effective for fat disruption but require patients with well-defined bulges for successful and safe treatment. Many patients, especially those with lower BMI, who desire body shaping procedure, are not suitable candidates. Furthermore, none of the procedures focus on the underlying musculature, which is highly responsible for toned and aesthetically pleasing abdominal appearance.

Besides physical exercise, electric and electromagnetic stimulation has been used for muscle training.^{6–8} Electromagnetic stimulation appears to dominate over the electrical stimulation as it induces double the peak torque,⁹ penetrates deeper into the tissue¹⁰ and is not associated with any pain⁹ or risks of burns.^{11,12} As electromagnetic stimulation has been shown to strengthen the muscles,^{9,13,14} and an intensive muscle training was shown to induce lipolysis,^{15,16} we hypothesize that the concept of electromagnetic stimulation can be applied for body shaping. Utilization of this technology would open possibilities for the patients not suitable for other procedures since the penetration of the magnetic field is not restricted by fat deposits.

Recently, there has been an introduction of a novel device (EMS-CULPT, BTL Industries, Boston, MA) utilizing a high-intensity focused electromagnetic (HIFEM) field with frequencies inducing tonic muscle contractions. The study aims to examine the effect of the HIFEM technology on patients' waist circumference, the effect on abdominal appearance, the treatment satisfaction, and the safety of the procedure and to investigate the suitability of the treatment for lower BMI patients.

2 | MATERIALS AND METHODS

A total of 22 patients (avg. BMI $23.8 \pm 3.3 \text{ kg m}^{-2}$) desiring aesthetic improvement of the abdomen voluntarily participated in this study. The patients' age ranged from 20 to 47 years with an average of 32 ± 7.1 years. Exclusion criteria included pregnancy, cardiac pacemakers, implanted electronic devices, metal implants, heart disorders, and any medical conditions contraindicating the use of the electromagnetic field. The study protocol conformed to the ethical guidelines of the 1975 Declaration of Helsinki and was approved by the Institutional Review Boards (IRB).

The patients underwent treatment of the abdomen by a device utilizing high-intensity focused electromagnetic field (EMSCULPT, BTL Industries, Boston, MA). The entire procedure consisted of 4 sessions distributed across two weeks (twice weekly, separated by 2–3 days). Each session lasted for 30 minutes during which the operator monitored the patients. Prior to treatment, informed consent was obtained from each patient.

The treatment was applied in a supine position with the device applicator positioned over the umbilicus. The targeted muscles were

the rectus abdominis, external and internal obliques. The applicator position was being adjusted at the beginning of the treatment to ensure homogeneously distributed contractions. The applicator was secured by a fixation belt to avoid any movement of the applicator during the treatment. The initial stimulation intensity was set according to patients' tolerance threshold and was further increased during the treatment once the patients got used to the muscle contractions. Over the course of a single session, most patients were able to reach an intensity of 90%–100%. No anesthesia was required.

To evaluate the treatment, weight, and waist circumference measurements, as well as frontal and lateral digital photographs, were taken before treatment, after the last treatment, and during a 3-month follow-up. Randomized digital photographs taken at baseline and during 3-month follow-up were given to three blinded evaluators for recognition. Furthermore, patient satisfaction with the treatment results was assessed using a 5-Likert scale questionnaire after the last treatment and during a 3-month follow-up. All data were tested by *t* test.

3 | RESULTS

The full study protocol was completed by 19 subjects (3 men, 16 women); 3 subjects opted out for reasons unrelated to the study. The results presented herein therefore comprise data from 19 patients.

Immediately after the last treatment, the waist circumference was significantly ($P < 0.01$) reduced on average by $3.29 \pm 1.9 \text{ cm}$. This further improved three months after the last treatment, with the average reduction reaching $4.37 \pm 2.63 \text{ cm}$ compared to baseline. The total average circumference can be seen in Figure 1.

Circumferential reduction in 16 out of 19 subjects (84%) exceeded 2.5 cm at month 3 post-treatment. These results were independent of weight changes ($P > 0.05$). A significant portion of the reduction (75%) was measured after the last treatment, further improving at month 3. The waist circumference of 1 patient increased immediately post-treatment number 4, and 2 patients (10.5%) did not have any waist size change at the follow-up. The waist reduction was found to be independent of the baseline BMI ($P < 0.05$). The individual results can be seen in Figure 2. Patients' weight did not change significantly ($P > 0.05$) throughout the measurements.

On average, the evaluators successfully recognized the before images from the 3-month images in 89.47% of cases. In 15 patients (79%), the images were uniformly recognized by all 3 evaluators. The successful recognition rate was positively correlated with the amount of circumference reduction ($P < 0.01$). Example of patient photographs can be seen in Figures 3 and 4.

Analysis of the patient questionnaire revealed that 89% of patients were satisfied with the treatment results immediately after the last treatment. During the 3-month follow-up visit, the satisfaction increased as all patients reported a certain degree of satisfaction. The patient satisfaction was independent of the amount of waist size reduction. After the last treatment, 95% of the patients

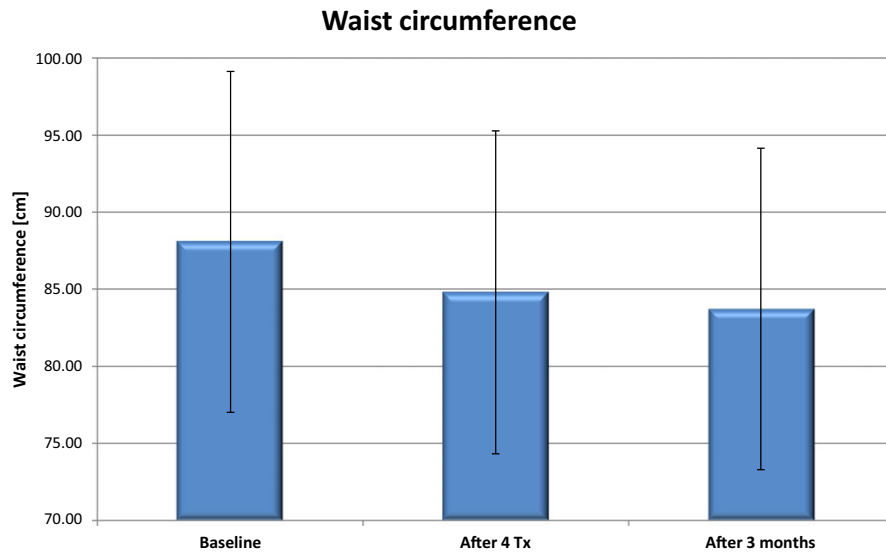


FIGURE 1 Average waist circumference at baseline, after fourth treatment and 3 months after last treatment

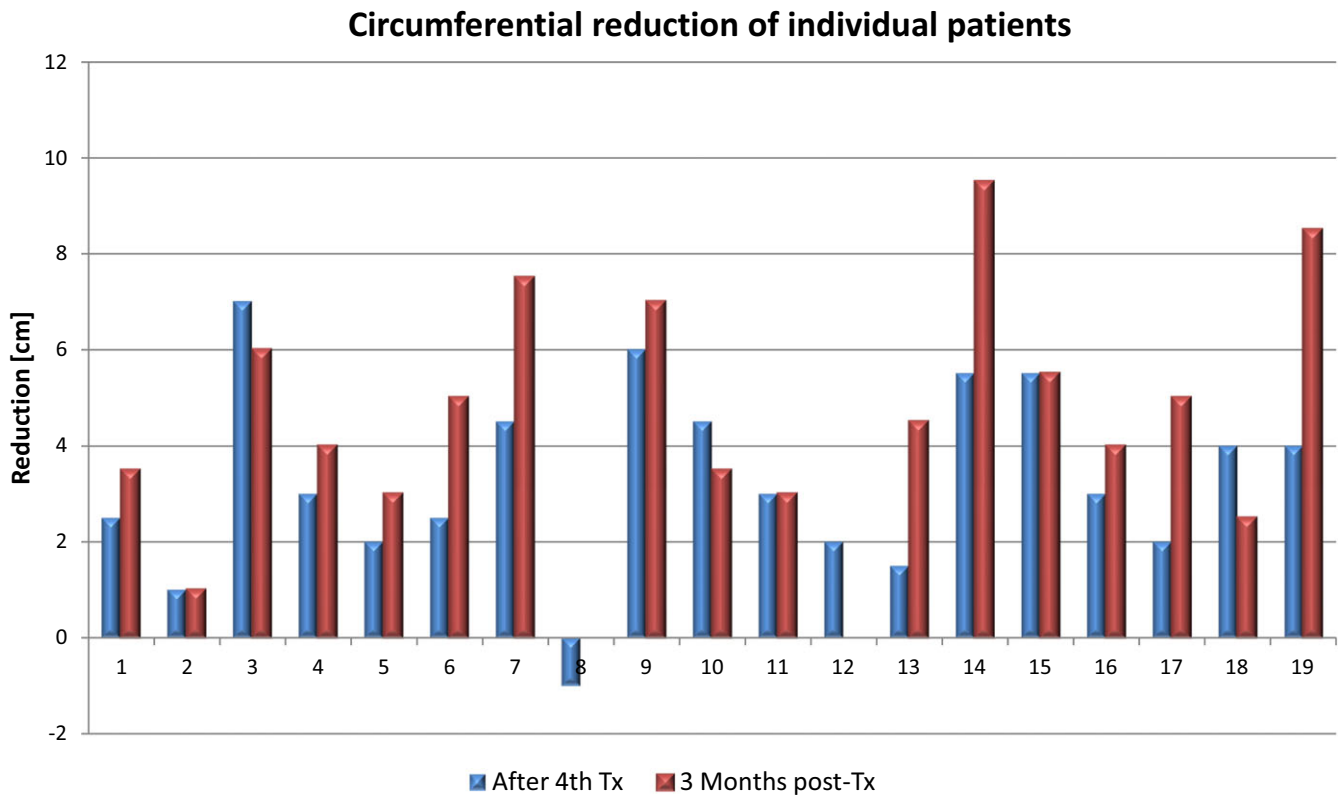


FIGURE 2 The individual waist circumference reduction measured immediately after the last treatment and during the 3-month follow-up

reported that they would recommend the treatment to a friend, while this decreased to 90% during the 3-month follow-up. Also, 89% of patients reported that their abdominal appearance improved immediately after the last treatment and this self-report further increased to 95% at month 3 follow-up. In general, the patient satisfaction improved at month 3 compared to evaluation after their last treatment, showing a similar trend as the measured waist reduction.

Muscle fatigue was a relatively frequent side effect that resolved within 12-48 hours. No adverse events were observed.

4 | DISCUSSION

Fifteen out of the 19 subjects had a BMI lower than 25, and the total average BMI was $23.8 \pm 3.3 \text{ kg m}^{-2}$. Many of the subjects

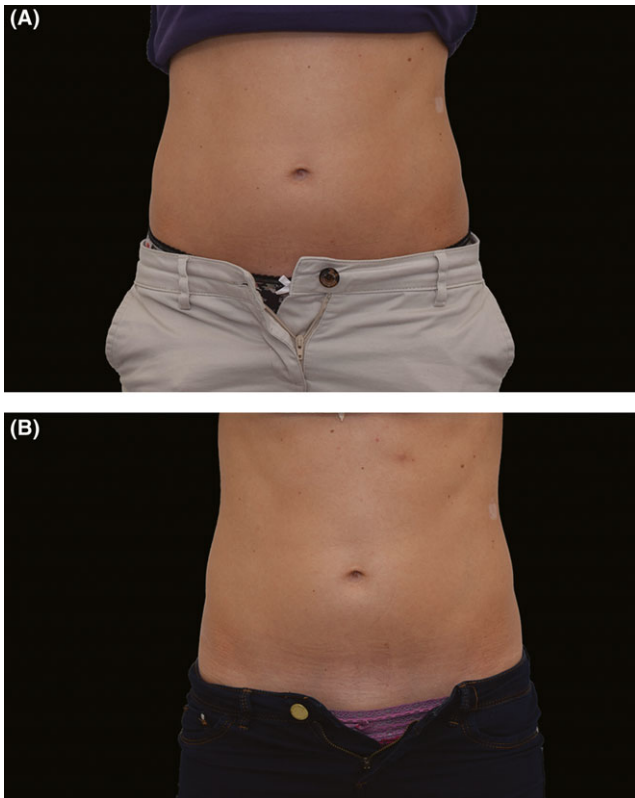


FIGURE 3 Digital images before (A) and 3 months after last procedure (B). Subject 13, age 30, BMI 18.9, waist circumference -3 cm (-4.0%), weight unchanged

would not be suitable candidates for fat debulking treatments, such as suction based or stamping fat reduction devices. The primary goal was to understand if HIFEM can be used for lower BMI patients who are not ideal candidates for other available technologies.

The presented results showed that the treatment of the abdomen utilizing the HIFEM technology was effective in reducing the patients' waist circumference and in improving the aesthetic appearance of the abdomen. This was accompanied with high patient satisfaction. The waist size reduction was present already after the fourth treatment and continued to further reduce over the course of 3 months in most patients. The fact that the amount of waist size reduction was not correlated with the baseline BMI, suggests that the treatment was effective at the same level for the study patients' BMI range (18.8–33.3). The patients were satisfied with the results, and the treatment was generally perceived as comfortable.

The visual aesthetic improvement was confirmed by a high rate of successful photograph recognition done by blinded independent evaluators. The rate of successful recognition was correlated with the amount of waist size reduction, indicating that the higher the waist size reduction, the more the aesthetic improvement of the subject.

The study found that a significant weight loss did not accompany the waist size reduction. The device delivers pulses in a frequency that produces supramaximal contractions not achievable voluntarily. The muscle does not have time to relax between the 2 consecutive stimuli

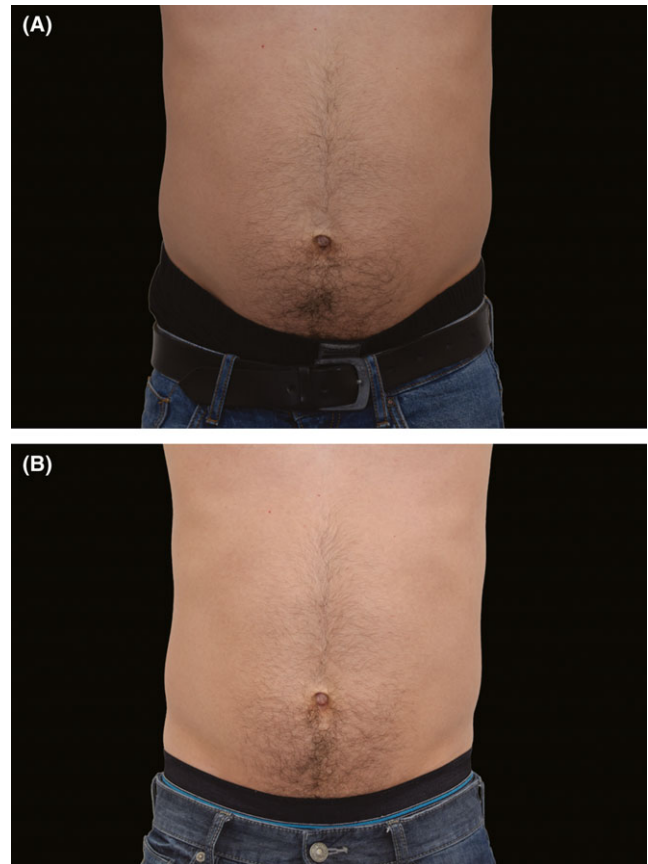


FIGURE 4 Digital images before (A) and 3 months after last procedure (B). Subject 11, age 33, BMI 25.2, waist circumference -7 cm (-7.7%), weight change -1.8 kg (-2.2%)

and is exposed to the extreme condition, which triggers a stress response in the tissue. Energy for supplying the contractions is taken from the fat cells presumably through lipolysis. The same effect, when muscles begin to use lipolysis as an energy supply, has already been seen during intense acute resistance exercise.^{15,16} Further, when regularly exposed to these conditions, the muscle needs to adapt to them, which leads to a volumetric growth of muscle (hypertrophy)^{17,18} and possibly hyperplasia.¹⁹ The waist circumference reduction can therefore result from both fat reduction and strengthening and tightening of the abdominal wall. The lack of weight loss after the treatment thus appears to be logical effect since the weight of lost fat tissue is compensated by the weight of gained muscle volume.

In comparison to other technologies for noninvasive body shaping, the HIFEM showed competitive results regarding the waist circumference reduction. A study by Ferraro et al²⁰ on cryolipolysis reported circumference reduction of 6.86 cm, an LLLT study by Savoia et al²¹ reported waist reduction as much as 6.83 cm, and RF study by Fajkosova et al²² showed 4.93 cm. Studies on HIFU^{23–25} showed a reduction of 4.1–4.7 cm. Looking at these results, the average waist reduction of 4.37 cm observed in the present study is highly competitive. However, the reduction presented in the mentioned studies is attributed to the fat loss, while the reduction in the present study appears to be a combined effect of a fat loss and strengthening of the abdominal wall muscles.

5 | CONCLUSION

The overall results are competitive in the noninvasive field of abdominal aesthetic improvement. The waist size reduction and improvement seen in photographs were driven by a combination of reduced fat and strengthened abdominal muscles. HIFEM treatments are effective for body shaping in both lower and medium BMI patients due to its effect on 2 tissues, showing high levels of patient satisfaction coupled with visible aesthetic improvement. We conclude the technology is ideal for treating patients who might not be candidates for other exiting technologies or whose problem is driven by a combination of fat deposits and underlying muscle laxity.

DISCLOSURE

Carolyn I. Jacob MD is medical advisor for BTL. Katya Paskova MD has no financial interest to declare in relation to any of the products or device mentioned in this article.

REFERENCES

- Pritchard M, Cramblitt B. Media influence on drive for thinness and drive for muscularity. *Sex Roles*. 2014;71(5–8):208–218. <https://doi.org/10.1007/s11199-014-0397-1>.
- Kruger J, Lee C-D, Ainsworth BE, Macera CA. Body size satisfaction and physical activity levels among men and women. *Obesity*. 16(8), 1976–1979. <https://doi.org/10.1038/oby.2008.311>.
- The American Society for Aesthetic Plastic Surgery. *Procedural Statistics*; 2017. <https://www.surgery.org/sites/default/files/ASAPS-Stats2017.pdf>. Accessed May 29, 2018.
- Mordon S, Plot E. Laser lipolysis versus traditional liposuction for fat removal. *Expert Rev Med Devices*. 2009;6(6):677–688. <https://doi.org/10.1586/erd.09.50>.
- Kennedy J, Verne S, Griffith R, Falto-Aizpurua L, Nouri K. Non-invasive subcutaneous fat reduction: a review. *J Eur Acad Dermatol Venereol*. 2015;29(9):1679–1688. <https://doi.org/10.1111/jdv.12994>.
- Langeard A, Bigot L, Chastan N, Gauthier A. Does neuromuscular electrical stimulation training of the lower limb have functional effects on the elderly?: A systematic review. *Exp Gerontol*. 2017;91 (Suppl C):88–98. <https://doi.org/10.1016/j.exger.2017.02.070>.
- Matsuse H, Hashida R, Takano Y, et al. Walking exercise simultaneously combined with neuromuscular electrical stimulation of Antagonists resistance improved muscle strength, physical function, and knee pain in symptomatic knee osteoarthritis: a single-arm study. *J Strength Cond Res*. 2017;31(1):171–180. <https://doi.org/10.1519/JSC.0000000000001463>.
- Lin VW, Hsieh C, Hsiao IN, Canfield J. Functional magnetic stimulation of expiratory muscles: a noninvasive and new method for restoring cough. *J Appl Physiol Bethesda Md* 1985. 1998;84(4):1144–1150.
- Han T-R, Shin H-I, Kim I-S. Magnetic stimulation of the quadriceps femoris muscle: comparison of pain with electrical stimulation. *Am J Phys Med Rehabil*. 2006;85(7):593–599. <https://doi.org/10.1097/01.phm.0000223239.93539.fe>.
- Zborowski M, Androjna C, Waldorff EI, Midura RJ. Comparison of Therapeutic Magnetic Stimulation With Electric Stimulation of Spinal Column Vertebrae. *IEEE Trans Magn*. 2015;51(12):1–9. <https://doi.org/10.1109/TMAG.2015.2458297>.
- Balmaseda MT, Fatehi MT, Koozekanani SH, Sheppard JS. Burns in functional electric stimulation: two case reports. *Arch Phys Med Rehabil*. 1987;68(7):452–453.
- Lambert H, Baetselier ED, Vanalme G, Mey GD. Skin burn risks using transcutaneous direct current. In: Proceedings of 17th International Conference of the Engineering in Medicine and Biology Society. 1995; 1: 647–648. <https://doi.org/10.1109/IEMBS.1995.575293>.
- Galloway N, El-Galley R, Sand PK, Appell RA, Russell HW, Carlan SJ. Extracorporeal magnetic innervation therapy for stress urinary incontinence. *Urology*. 1999;53(6):1108–1111. [https://doi.org/10.1016/S0090-4295\(99\)00037-0](https://doi.org/10.1016/S0090-4295(99)00037-0).
- Abulhasan JF, Rumble Y, Morgan ER, Slatter WH, Grey MJ. Peripheral electrical and magnetic stimulation to augment resistance training. *J Funct Morphol Kinesiol*. 2016;1(3):328–342. <https://doi.org/10.3390/jfmk1030328>.
- Chatzinikolaou A, Fatouros I, Petridou A, et al. Adipose tissue lipolysis is upregulated in lean and obese men during acute resistance exercise. *Diabetes Care*. 2008;31(7):1397–1399. <https://doi.org/10.2337/dc08-0072>.
- Ormsbee MJ, Thyfault JP, Johnson EA et al. Fat metabolism and acute resistance exercise in trained men. *J Appl Physiol Bethesda Md* 1985. 2007;102(5):1767–1772. <https://doi.org/10.1152/jappphysiol.00704.2006>.
- Charette SL, McEvoy L, Pyka G, et al. Muscle hypertrophy response to resistance training in older women. *J Appl Physiol*. 1991;70 (5):1912–1916.
- Schoenfeld BJ. The mechanisms of muscle hypertrophy and their application to resistance training. *J Strength Cond Res*. 2010;24 (10):2857–2872. <https://doi.org/10.1519/JSC.0b013e3181e840f3>.
- Alway SE, Grumbt WH, Gonyea WJ, Stray-Gundersen J. Contrasts in muscle and myofibers of elite male and female bodybuilders. *J Appl Physiol Bethesda Md* 1985. 1989;67(1):24–31.
- Ferraro GA, De Francesco F, Cataldo C, Rossano F, Nicoletti G, D'Andrea F. Synergistic effects of cryolipolysis and shock waves for noninvasive body contouring. *Aesthetic Plast Surg*. 2012;36(3):666–679. <https://doi.org/10.1007/s00266-011-9832-7>.
- Savoia A, Landi S, Vannini F, Baldi A. Low-level laser therapy and vibration therapy for the treatment of localized adiposity and fibrous cellulite. *Dermatol Ther*. 2013;3(1):41–52. <https://doi.org/10.1007/s13555-013-0026-x>.
- Fajkošová K, Machovcová A, Onder M, Fritz K. Selective radiofrequency therapy as a non-invasive approach for contactless body contouring and circumferential reduction. *J Drugs Dermatol JDD*. 2014;13(3):291–296.
- Fatemi A. High-intensity focused ultrasound effectively reduces adipose tissue. *Semin Cutan Med Surg*. 2009;28(4):257–262. <https://doi.org/10.1016/j.sder.2009.11.005>.
- Fatemi A, Kane M. High-intensity focused ultrasound effectively reduces waist circumference by ablating adipose tissue from the abdomen and flanks: a retrospective case series. *Aesthetic Plast Surg*. 2010;34(5):577–582. <https://doi.org/10.1007/s00266-010-9503-0>.
- Teitelbaum SA, Burns JL, Kubota J, et al. Noninvasive body contouring by focused ultrasound: safety and efficacy of the Contour I device in a multicenter, controlled, clinical study. *Plast Reconstr Surg*. 2007;120(3):779–789; discussion 790. <https://doi.org/10.1097/01.prs.0000270840.98133.c8>.

How to cite this article: Jacob CI, Paskova K. Safety and efficacy of a novel high-intensity focused electromagnetic technology device for noninvasive abdominal body shaping. *J Cosmet Dermatol*. 2018;17:783–787. <https://doi.org/10.1111/jocd.12779>